Innovative trends in flexor tendon repair using the first annular pulley as a graft for pulley reconstruction

Gilberto O'Hara, MD*, Osvandré Lech, MD†, and Antônio Severo, MD†

Flexor tendon laceration in zone II remains a difficult problem for the hand surgeon. Pulley reconstruction is essential for the accurate gliding mechanism of the repaired tendon. We present new options for the reconstruction of the A2 pulley using the A1 pulley as a graft. The A1 pulley can be dissected at the volar plate of the metacarpophalangeal joint, obtaining one or two segments approximately 5 mm long to be used as a graft. There are different techniques for harvesting the pulley graft, such as the tubular, open, slide, and strip techniques.

*Orthopaedic Surgery Department, Hand and Upper Extremity Division, UNIFESP-EPM, São Paulo, Brazil. †Residency Program, Institute of Orthopaedics and Traumatology (IOT), Passo Fundo, Brazil.

Current Opinion in Orthopedics 1998, 9;IV:6–10

ISSN 1041–9918

Much of the current literature regarding flexor tendon injury has centered around repair techniques [1,2••–5••] and postoperative management [6••,7••,8•]. Although these have aided in the management of tendon injury acutely, one area that has not received much attention is management of chronic flexor tendon injuries [9,10•,11,12,13••,14•,15•,16,17,18••,19].

Chronic flexor tendon rupture/laceration/adhesion in Zone II have proven to be a formidable challenge for hand surgeons because of the necessity to reconstruct the lacerated or adherent flexor tendons and the pulley system simultaneously.

Doyle and Blythe [20] showed that the A2 and A4 pulleys are essential and necessary for complete excursion of the profundus flexor tendon in the digits. Bunnell [1]; Kleinert and Bennet [11], Wray and Weeks [19], Bader *et al.* [9], and Lister [12], among several others, use different techniques and materials to reconstruct the A2 and A4 pulleys; however, each one of these techniques has shown advantages and disadvantages.

Ohara [16] demonstrated by anatomic studies that is possible to obtain a tubular segment of the undamaged A1 pulley. Thus, it can be used as a pulley graft to provide repair of another damaged pulley (A2 or A4).

The purpose of this article is to present the surgical technique and to verify the feasibility of using an A1 pulley graft for treatment of chronic flexor tendon lesions in the Zone II of the hand with destruction of the pulley system.

Technique

The A1 pulley is a 20-mm fibrous tunnel structure that maintains the flexor tendon in contact with the underlying skeletal architecture. It can be carefully dissected at the volar plate of the metacarpophalangeal joint, obtaining one or two segments of approximately 5 mm long that can then be used as a graft.

The reconstruction of the A2 and A4 pulleys using A1 pulley as a donor graft can be done by four different methods—tubular, open, slide, and strip. They can be positioned and sutured to the remaining soft tissue at the desired place to reconstruct the A2 pulley, A4 pulley, or both.

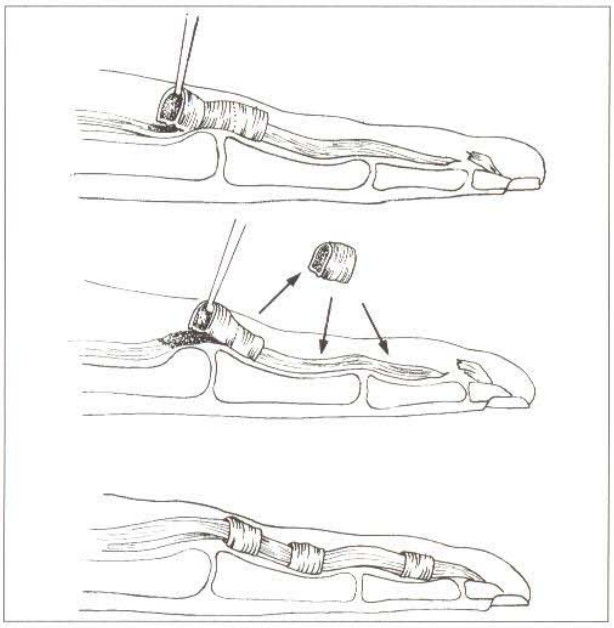

Fig. 1. Tubular graft type.

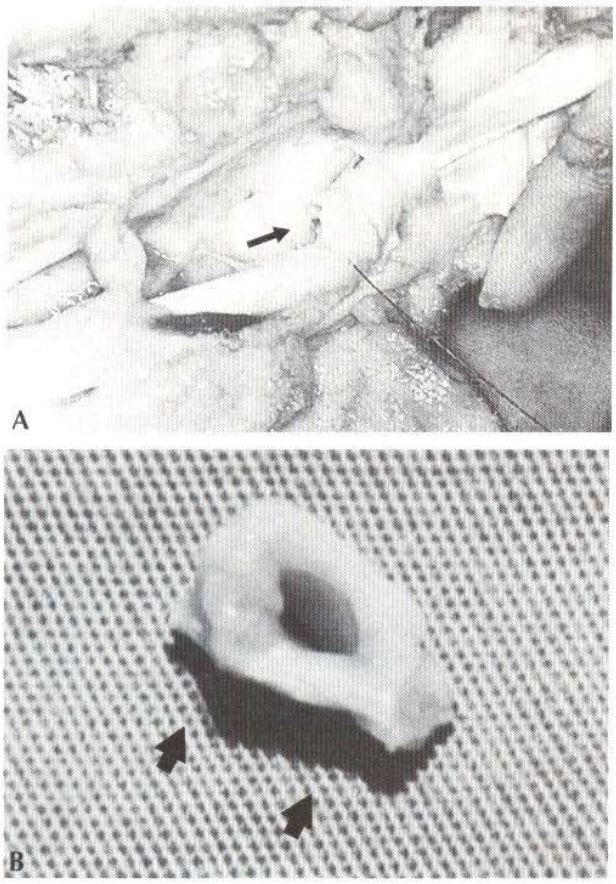

Fig. 2. Tubular graft type. **A,** Dissection from the volar plate and detachment as a tubular segment (*arrow*). **B,** The dissected area from the volar plate is indicated by the *arrows* (tubular graft).

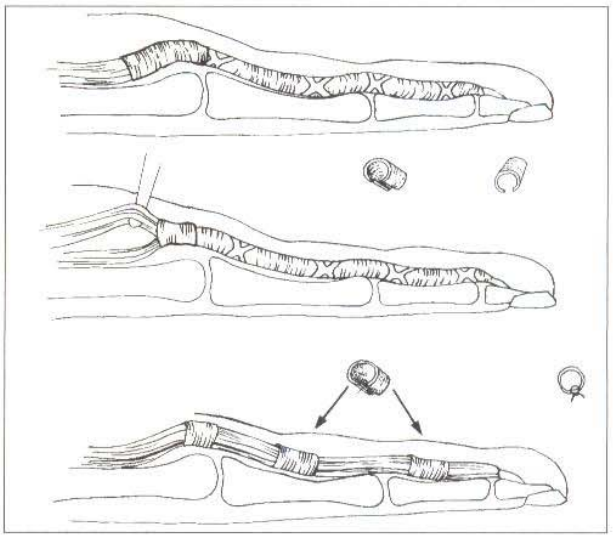

Fig. 3. Open graft type.

The clinical status of the damaged flexor tendons (intact but adherent, profundus and/or superficialis rupture, absent) and pulley system (intact but adherent, partially destroyed, absent) determines which model should be used. When the A1 pulley of the finger to be repaired is also damaged, it is possible to obtain it from the adjacent, undamaged finger using the same techniques. The greatest advantage of this technique is that both procedures (tendon and pulley system reconstruction) can be done at the same time.

Tubular graft

In the chronic ruptured flexor tendon lesion with A2 or A4 pulley destruction, when the A1 pulley is preserved, one or two 5-mm-long tubular segments can be obtained. Then it is positioned and fixed to the remaining soft tissue bed of the damaged A2 or A4 pulley. After that, the profundus flexor tendon or a tendon graft is passed through the inner part of the new pulley system and repaired (Figs. 1 and 2).

Open graft

When the flexor tendon is not ruptured, a graft from the A1 pulley can be obtained by dividing it longitudinally and harvesting. Then the graft is placed in the desired A2 or A4 position, sutured back to recover its tubular structure, and fixed to the remaining soft tissue bed of the damaged pulley system (Figs. 3 and 4).

Slide graft

When fibrous adhesions of an undamaged or repaired flexor tendon limit tendon excursion and hence active motion and the A2 or A4 pulley is damaged, a primary tenolysis is performed first; then, a tubular graft of the A1 pulley is dissected and detached, sliding it to the desired location. Again, it is sutured to the remaining soft tissue of damaged pulleys (Fig. 5).

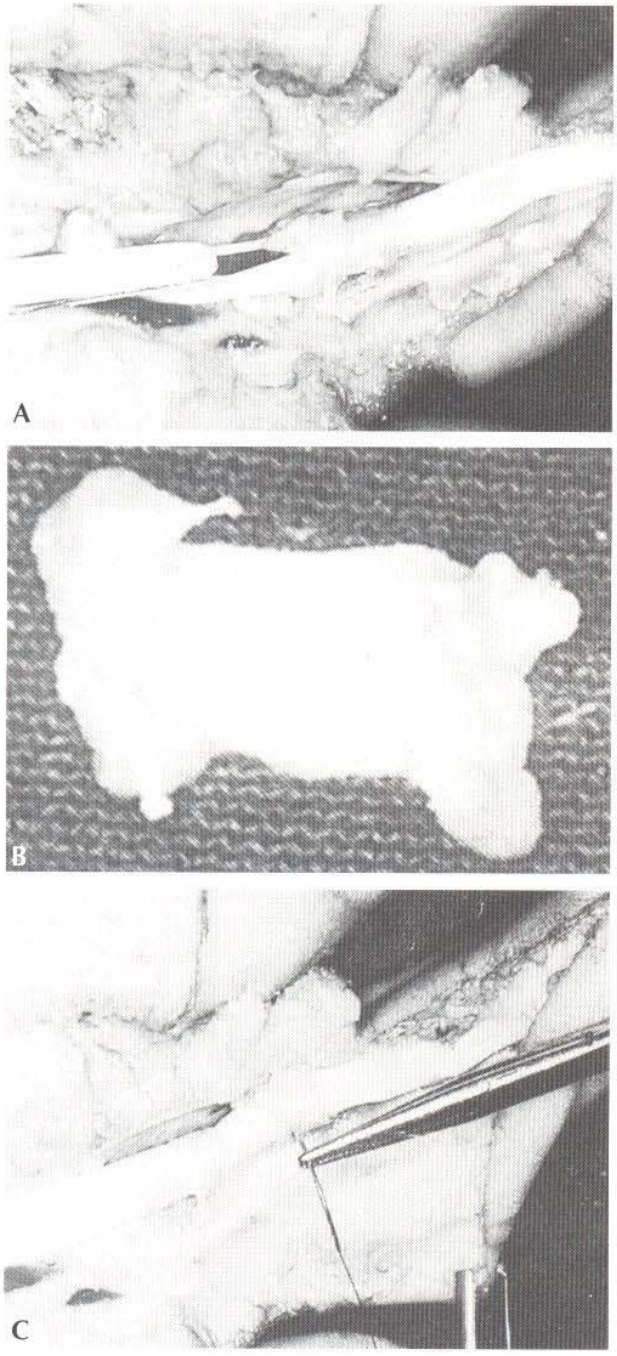

Fig. 4. Open graft type. **A,** A1 pulley graft is incised longitudinally to be harvested. **B,** Inferior view of the inner part of the open graft type. **C,** At the desired A2 or A4 place, the graft covers the flexor tendon and is sutured back, recovering its tubular format. The graft is then turned around to keep the dissected plane in contact with the bone surface.

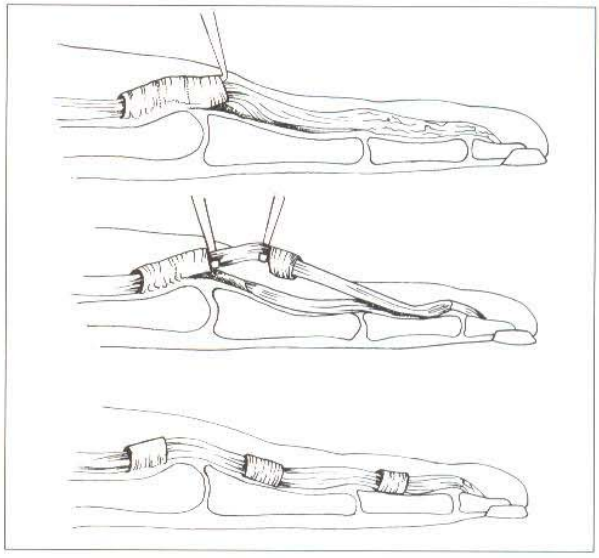

Fig. 5. Slide graft type.

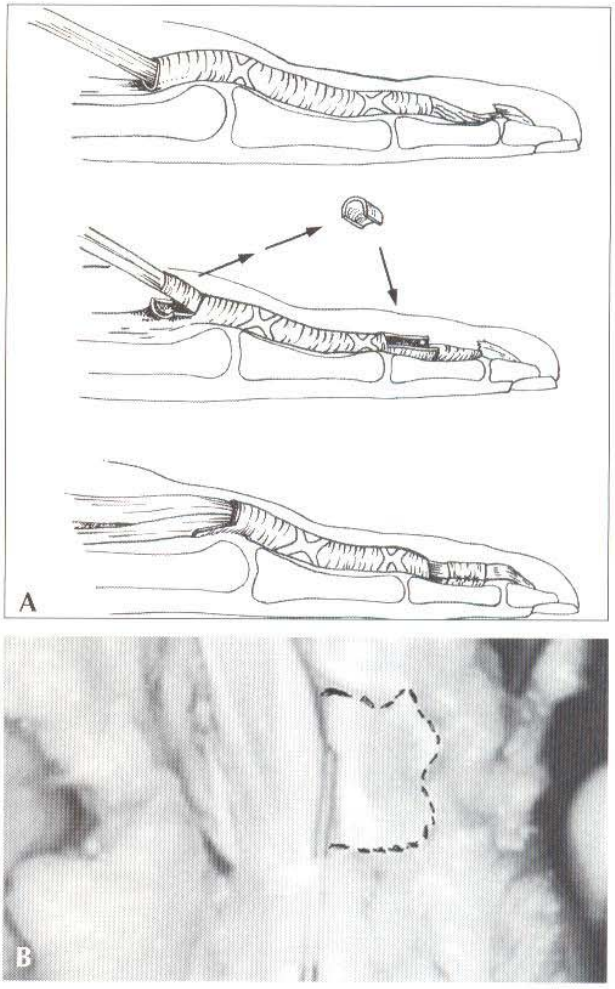

Fig. 6. A, Strip graft type. **B,** The upper part of A1 pulley (*dotted lines*) can be used as a strip graft.

Table 1

Title

Patient	Age	Sex	Digit	Surgical Procedure	Result at 4–6 mo (fingertip–palm distance)
1 HO	23	F	Index	FDS/FDP tenolysis, two slide grafts to A2/Ar	1.5cm
2 MO	37	F	Small	FDP tenorraphy, tubular graft to A4	3.0 cm
3 MAN	29	F	Index	Tendon graft to FDP, tubular graft to A2	2.0 cm
4 AMV	42	F	Index/middle	FDP Tenorraphy, two tubular grafts to A2/Ar	3.0 CM index 2.5 cm middle
5 ACM	41	M	Ring	FDS/FDP tenolysis, open graft to A4	Contact
6 WS	27	F	Index	Tendon graft to FDP, two open grafts (from the middle) to A2/Ar of the index	4.0 cm
7 ENF	35	M	Middle	FDP tenorraphy, strip graft to A4	2.5 cm
8 EHA	08	M	Index	Tendon graft to FDP, two strip grafts to A2/A4	5.0 cm

Strip graft

When the floor of the A2 or A4 pulley is preserved, a strip of 5 mm to 7 mm of the upper part of the A1 pulley is obtained and sutured to the remaining portion of the damaged pulley, restoring the needed retinacular tunnel. This technique is most applicable for pulley reconstruction in a pediatric hand because of technical difficulties of obtaining a tubular graft at this age (Fig. 6).

Material and methods

This technique has been used in eight clinical cases described later in this preliminary report. All patients were involved in the same postoperative rehabilitation program, which consisted of 2 weeks of immobilization followed by a dynamic Kleinert splinting program; active motion was started at the fourth or fifth week. Several variables influenced the final clinical result: the type of the lesion according to Boyes [1]; the elapsed time since the injury; the use of tendon graft; joint stiffness; and contractures. All patients are listed in the Table 1.

Although total active motion as limited in may patients, active tendon excursion without "bowstringing" was demonstrated in all cases and represented a significant improvement over the preoperative state of no excursion. Patient satisfaction was high, and no incidence of donor site morbidity occurred.

Discussion

Reconstruction of the essential pulleys (A2 and A4) using the technique described here has proven to be a good option in the hand surgeon armamentarium [16,17]. Because of its versatility, the surgeon is able to choose among four different, easily accessible graft types (i.e., tubular, open, slide, and strip graft), according to the specific damage to the flexor system (tendon and pulley). Another important aspect is that the pulley replacement is performed by a similar tissue, not by the palmaris longus, superficialis tendon, or another material that can lead to further adherence.

It has been the authors' experience that when one chooses the A1 pulley as a graft, either from the injured or the adjacent, undamaged digit, he or she can feel comfortable that minimal functional impairment at the donor site area will occur. The series presented is still small but promising. With a longer follow-up, a better understanding of the new technique will be possible.

Conclusions

The authors present a technique for reconstruction of the A2 and A4 pulleys of the hand using the A1 pulley as a graft. Four models are described—tubular, open, slide, and strip. They can be chosen according to the clinical situation found at the time of the exploratory surgery.

References and recommended reading

Papers of particular interest, published within the annual period of review, have been highlighted as:

- • Of special interest
- •• Of outstanding interest

1. Bunnell S: In Bunnell's Surgery of the Hand. Edited by Boyes JH. Philadelphia: JB Lippincott. 1970: 393–456.

2. •• Hariharan JS, Diao E, Soejima O, Lotz JC: Partial lacerations of human digital flexor tendons: a biomechanical analysis. J Hand Surg [Am] 1997, 22:1011–1015.

To determine the loss of tensile strength with varying degrees of partial laceration, tensile tests were performed on two matched groups of human cadaver flexor tendons. One group had 50%, whereas the other had 75% transverse volar lacerations to the anteroposterior diameter. The mean failure load of the 50% lacerated tendons was 93% higher than that of the 75% lacerated tendons. The study demonstrates that the threshold load levels to rupture of 50% and 75% lacerations are higher than physiologic load levels measured during active motion, suggesting that partial flexor tendon lacerations of up to 75% can withstand *in vivo* forces associated with active, unresisted mobilization of the digital flexor tendon.

3. •• Ingari JV, Pederson WC: Update on tendon repair. Clin Plast Surg 1997, 24:161–171.

Zone II is historically the most challenging one for the surgeon attempting repair, largely owing to the high propensity of scarring between the in this area, which can lead to a compromised result after primary repair. They state that better clinical results are obtained when both flexor digitorum sublimis and flexor digitorum profundus were repaired compared with then only flexor digitorum profundus was repaired. Based on the available clinical information and most recent laboratory studies, surgical repair should be carried out on partial tendon lacerations of 60% or more, and tendons with less than 30% laceration should not be repaired. They state that the Tajima modification of the Kessler "grasping core suture" is superior in strength to a horizontal mattress suture technique for repair for zone II flexor digitorum sublimis tendon injuries.

4. Shaieb MD, Singer DI: Tensile strengths of various suture techniques. J
•• Hand Surg [Br] 1997. 22:764–767.

Two new suture methods, double and triple (modified) Kessler, were compared with the Savage, Indiana and modified Kessler techniques. All were core sutures without epitendinous sutures. The study found the Savage technique strongest, followed by the triple Kessler, the double Kessler, and finally the Indiana. The double Kessler was almost twice as strong as the modified Kessler. This study also compared two four-stranded technique (the Indiana and double Kessler) and found the double Kessler stronger. The double Kessler is a simple yet strong suture and may be useful for flexor tendon repairs.

5. Stahl S, Kaufman T, Bialik V: Partial lacerations of flexor tendons in
•• children. J Hand Surg [Br] 1997, 22:377–380.

The authors compared the outcome of 17 partially lacerated (less than 75% of cross-sectional area) flexor tendon in zones II and III in children treated by surgical repair to that of 19 tendon lesions treated conservatively by early mobilization. Magnetic resonance imaging, a noninvasive method of diagnosis, could be used in cooperative children in whom there was doubt about the size of the tear, thereby avoiding unnecessary surgical exploration. The outcome of both groups was similarly favorable. No complications such as triggering or complete tendon tear were found in either group. They suggest early mobilization in children in whom a partial division of flexor tendon is diagnosed clinically. Exploration should be carried out only in doubtful cases to exclude complete division of the tendon.

6. Aoki M, Kubota H, Pruitt DL, Manske PR: Biomechanical and histologic
•• characteristics of canine flexor tendon repair using early postoperative mobilization. J Hand Surg [Am] 1997, 22:107–114.

The purpose of this experimental study was to evaluate the mechanical and histologic healing of flexor tendon repairs using an early active motion model. Three different flexor tendon repair techniques in zone II were used. Smooth tendon gliding was obtained in all specimens in which repair was successful. They concluded that the improved suture techniques have the potential to withstand the stress produced by active digital motion protocols.

7. Khan K, Riaz M, Murison MC, Brennen MD: Early active mobilization after
•• second stage flexor tendon grafts. J Hand Surg [Br] 1997, 22: 372–374.

The authors report the results of nine two-staged tendon reconstructions using the ipsilateral palmaris longus tendon graft inserted into a tunnel that had been previously created by a silicone spacer. Early active motion was commenced 48 h after surgery according to a previously described protocol (Small *et al.*, 1989). All patients were seen at a minimum of 5 months after the second procedure. According to the total active motion criteria (Kleinert and Verdan, 1983), there were three excellent/good, five fair, and one poor result; when the Buck-Gramcko criteria (1976) were used, they found five excellent/good, two satisfactory, and two poor results, showing that the evaluation of the results is influenced by the method of analysis. They believe that the distal and proximal junctions and the tendon graft can all withstand the forces involved in early mobilization without resistance. The advantage of mobilization in preventing adhesions of the tendon apply equally to tendon grafts and primary tendon repair, and no benefit is obtained from immobilizing digits after tendon grafting.

8. Panchal J, Mehdi S, Donoghue JO, O'Sullivan T, O'Shaughnessy M, O'
• Connor TP: The range of excursion of flexor tendons in zone V: a comparison of active versus passive flexion mobilisation regimes. Br J Plast Surg 1997, 50:517–522.

The authors report their results in a study proposed to determine the range of motion of the flexor tendons in zone V and to compare the range of motion between active (Belfast) and passive (modified Duran) flexion mobilization regimes postoperatively. The measurement was done in two cadavers and two patients at four different times: intraoperatively and the 10th, 21st and 45th postoperative days. The results demonstrated an increased excursion of the repaired flexor tendons in zone V following an active flexion mobilization regime as compared to the passive one.

9. Bader KF, Sethi G, Curtin JW: Silicone pulleys and underlays in tendon surgery. Plast Reconstr Surg 1968, 41:157–164.

10. Guelmi K, Barbaato B, Kolb FL: Reconstruction of a metacarpophalangeal
• pulley in the thumb with a free extensor retinaculum graft. J Hand Surg [Br] 1997, 22:274–276.

This paper describes a new method of reconstruction of the pulley system of the thumb using the extensor retinaculum. A modified Lister's technique for reconstruction of A1 oblique pulley is used, and the fixation is similar to that proposed by Kleinert and Bennet (1978). A 2-cm-long strip of the extensor retinaculum is sutured on each side of the pulley remnants with firm anchorage.

11. Kleinert HE; Bennet JB: Digital pulley reconstruction employing the always present rim of the previous pulley. 1978, J Hand Surg [Am] 1978, 3:297–298.

12. Lister GD: Reconstruction of pulleys employing extensor retinaculum. J Hand Surg [Am]1979, 4:461–464.

13. Liu TK, Yang RS: Flexor tendon graft for late management of isolated
•• rupture of the profundus tendon. J Trauma 1997, 43:103–106.

The authors reviewed retrospectively the clinical outcome of flexor tendon grafting of 15 patients with isolated flexor digitorum profundus rupture. The mean follow-up was 31.3 months. 11 patients (73%) achieved active distal interphalangeal joint flexion greater than 30°, and four patients (27%) had it greater than 40°. Total active motion ranged from 145 to 230° (mean 180.7%), which accounts for 64% to 100% (mean 79.8%) of the normal total active motion. According to the criteria of Stark *et al.*, 12 patients (80%) had satisfactory results, and 3 had unsuccessful outcome. Flexor tendon grafting in the management of an isolated rupture of flexor digitorum profundus should be performed in properly selected patients: motivated and young, with full passive motion of all joints, minimal scarring of the finger, and normal function. Without these criteria, flexor digitorum profundus tenodesis or distal interphalangeal joint fusion should be considered.

14. Naam NH: Staged flexor tendon reconstruction using pedicled tendon
• graft from the flexor digitorum superficialis. J Hand Surg [Am] 1997, 22: 323–327.

The use of pedicled flexor digitorum superficialis tendon as a tendon graft in the second stage of flexor tendon reconstruction (Paneva-Holevich technique) has the advantage of using local intrasynovial tendon graft and allowing early active range of motion. He operated on 47 patients and obtained 64% of good and excellent results.

15. Netscher D, Lee M, Thornby J, Polsen C: The effect of division of the trans-
• verse carpal ligament on flexor tendon excursion. J Hand Surg [Am] 1997, 22:1016–1024.

The effect of the transverse carpal ligament as a pulley was evaluated by measuring flexor tendon excursion after ligament division and by changing wrist position through a range of flexion and extension (30° extension, neutral, 30° flexion, and 60° flexion). With increasing wrist flexion, greater excursion differences were noted. Analysis of variance revealed that for both flexor digitorum sublimis and flexor digitorum profundus, a significant difference in excursion occurred at 60° wrist flexion and 30° wrist extension with no ligament reconstruction or aponeurotic repair compared with values before carpal tunnel release and transposition ligament repair.

16. Ohara GH: Técnica de reconstrução de polias essenciais utilizando enxerto de polia no tratamento cirúrgico das lesões dos tendões flexores na zona II: Bases anatômicas. Rev Bras Ortop 1995, 30: 213–218.

17. Ohara GH, Albertoni W, Faloppa F, Sato K. Técnica de reconstrução de polias essenciais utilizando enxerto de polia no tratamento cirúrgico das lesões dos tendões flexores na zona II: Avaliação clínica. Rev Bras Ortop 1996, 31:75–82.

18. Soucacos PN, Beris AE, Malizos KN, Xenakis T, Touliatos A, Soucacos P:
•• Two-stage treatment of flexor tendon ruptures. Silicone rod complications in 109 digits. Acta Orthop Scand Suppl 1997, 275:48–51.

The authors analyzed the complications found in the two-staged flexor tendon reconstruction with silicone spacer in 89 patients (109 digits): Stage I: six distal end rupture, six rod migration, three infections, two rod buckling, one synovitis; Stage II: six loose graft, two distal ruptures, two tight graft, one bowstringing. Each of the complications were considered severe, with the potential of altering the final outcome from the point of elongating the duration of treatment with additional reoperations up to complete failure. They conclude that although staged flexor tendon reconstruction proved to successfully manage flexor tendon injuries in Zone II in mangled fingers, it bears a potential number of complications that can occur in both stages of the procedure.

19. Wray RC, Weeks PM: Reconstruction of digital pulleys. Plast Reconstr Surg 1974, 53:534–546.

20. Doyle J, Blythe WF: Anatomy of the flexor tendon sheath and pulleys of the thumb. J Hand Surg [Am] 1977, 2:149–151.